

## Case Report



# Major bleeding after proning in a patient with severe COVID-19: A case report

Rosanna Carmela De Rosa<sup>1\*</sup>, Michele Gallifuoco<sup>1</sup>, Antonio Romanelli<sup>2</sup>, Antonio Corcione<sup>1</sup>

<sup>1</sup>Department of Anaesthesia and Intensive Care Monaldi Hospital, AORN dei Colli, Leonardo Bianchi Street, 80131 Naples, Italy

<sup>2</sup>AOU San Giovanni di Dio e Ruggi D'Aragona, Department of Anaesthesia and Intensive Care, San Leonardo Street, 1, 84131, Salerno, Italy

### Article info

#### Article History:

Received: 17 Nov. 2020

Accepted: 24 Dec. 2020

e-Published: 2 Feb. 2021

#### Keywords:

- Anticoagulant therapy
- ARDS
- Bleeding
- COVID-19
- Thrombosis
- Proning

### Abstract

Contrarily to the severe acute respiratory syndrome coronavirus (SARS) and Middle East respiratory syndrome coronavirus (MERS), the evidence suggests that thromboembolic events are common in patients with COVID-19 pneumonia. The clinical course of severe COVID-19 patients can be complicated with coagulopathy, causing fatal thromboembolic events and requiring adequate treatment with anticoagulant therapy. However, the clinicians should be alert about the increase of bleeding related to aggressive anticoagulation protocols, especially in critically ill patients who undergo traumatic maneuvers. Here, we reported the case of a 55-year-old woman with symptomatic COVID-19 pneumonia, admitted to the intensive care unit (ICU) and treated with anticoagulant therapy complicated by major bleeding, probably related to prone positioning for the treatment of acute respiratory distress syndrome (ARDS).

### Introduction

Contrary to previous coronavirus epidemic, the severe acute respiratory syndrome coronavirus (SARS) in 2002 and Middle East respiratory syndrome coronavirus (MERS) in 2012, studies reported a high incidence of venous thromboembolism and acute pulmonary embolism (APE) in critically ill patients with COVID-19 who were treated at the intensive care unit (ICU); it was at least 2 times higher compared to other critically ill patients,<sup>1,2</sup> with a mortality rate of 40%. Proposed underlying mechanisms include an exaggerated cytokine storm, endothelial dysfunction/injury, and hypercoagulability. Elevated inflammatory and coagulation markers such as D-dimer and fibrinogen as well as neutrophilia have been associated with increased mortality in COVID-19.<sup>3</sup>

Therefore, clinicians should be alert to the thromboembolic events, which can be fatal in patients with COVID-19 pneumonia, and treat them quickly with anticoagulant therapy.<sup>4</sup>

A multicentre observational study<sup>5</sup> on prophylactic and therapeutic management of thromboembolic events in patients with COVID-19 showed that 8.0% of patients experienced hemorrhagic complications, of which 4.8% were classified as major bleeding, without the occurrence of disseminated intravascular coagulation (DIC). Gastrointestinal bleeding was the most common site,

followed by bleeding related to traumatic maneuvers (i.e., tracheostomy).

With the aim to improve gas exchange and treat acute respiratory distress syndrome (ARDS), prone position ventilation is mandatory in COVID-19 critically ill patients.<sup>6</sup> In this cluster of patients receiving anticoagulant therapy, pronation and position change can be considered as traumatic events, with a risk of hidden or unusual site of bleeding. Actually, in the literature, hemorrhagic risk related to prone position in COVID-19 patients is not reported.

Here, we report the case of a 55-year-old woman with severe COVID-19 pneumonia, admitted to the ICU and treated with low weight molecular heparin (LWMH) plus aspirin, complicated by DIC due to major bleeding in unusual site (abdominal wall muscles), probably related to prone position cycles ventilation to treat ARDS.

### Case Presentation

On April 4, 2020, a confirmed SARS-CoV-2 infected woman, 55-year-old, 65 kg, without previous comorbidities, requiring mechanical ventilation with tracheal intubation, was admitted to the ICU at Monaldi Hospital (AORN Ospedale dei Colli, Naples).

On admission, her chest computed tomography (CT) showed a lung picture pattern like ARDS, extensive

\*Corresponding Author: Rosanna Carmela De Rosa, Email: rosderosa.rdr@gmail.com

consolidations, and reduced aerated lung size (“baby lung”), which accounts for low pulmonary compliance ( $<45$  mL/cmH<sub>2</sub>O) and PaO<sub>2</sub>/FiO<sub>2</sub>  $<100$  mm Hg. A “white lung” pattern was observed on lung ultrasound examination. A 12-derivations ECG, arterial blood gas analysis, blood samples for laboratory cell-blood count, liver (AST, ALT, bilirubin) and renal (urea, creatinine) functions, coagulation (aPTT, PT, INR, D-dimer, fibrinogen), cardiac injury markers (troponin I, CK-MB), procalcitonin, and inflammation markers (PCR, IL-6) were performed daily or repeated based on clinical changes and therapeutic adjustments. The coagulation exams showed markedly elevated D-dimer levels (1600 ng/mL on admission and always above the cut-off value of 500 ng/mL), without clinical and ultrasound signs of deep vein thrombosis.

Heart rate, body temperature, invasive blood pressure, diuresis, and SpO<sub>2</sub> were monitored. We sedated the patient with propofol (2-4 mg/kg/h) and remifentanyl (0.1-0.5 mcg/kg/min). Because of the patient’s reduced pulmonary compliance ( $<50$  mL/cmH<sub>2</sub>O) and after neuromuscular blockade (rocuronium, IV, 0.7 mg/kg one shot, followed by a continuous infusion rate of 0.4-0.7 mg/kg/h), we applied conventional lung-protective strategy ventilation with higher PEEP (driving pressure  $<15$  cmH<sub>2</sub>O), lower tidal volume (6 mL/kg), prone position cycles (at least 18 hours), recruiting maneuvers, and permissive hypercapnia, keeping SpO<sub>2</sub> target between 92-96%. Lung recruitment was evaluated by daily lung ultrasound (A and B Lines, consolidations) and PaO<sub>2</sub>/FiO<sub>2</sub>. For fluid management a conservative fluid strategy was performed to obtain a daily negative balance in order to avoid an increase in “lung water”, evaluated by lung-heart ultrasound (B-lines, white lung, volume overload).<sup>7,8</sup>

To prevent thromboembolic complications, the patient received twice a day LWMH (enoxaparin 6000 UI, sc) plus aspirin (100 mg os, once a day).

She received hydroxychloroquine (200 mg, per os, twice a day) and glucocorticoids (methylprednisolone IV, 0.5 mg/kg twice a day for 5 days, then 20 mg twice a day for 5 days, finally, 10 mg twice a day).

After two cycles of prone positioning ventilation, PaO<sub>2</sub>/FiO<sub>2</sub> value significantly improved ( $>250$  mm Hg), and the lung ultrasound showed A-lines with a reduction in B-lines. Due to her improved clinical condition after a week, weaning began and ended successfully two days later. Non-invasive ventilation was not required after extubation.

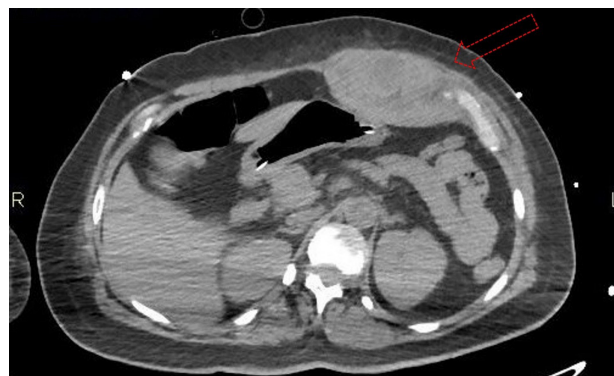
During the weaning, clinicians noted the development of slow anemia, with hemoglobin (Hb) value above 8 gr/dL, and treated with blood transfusion. At first, the clinicians suspected that anemia was related to the hyperinflammatory state. The absence of a clear source of bleeding, hemodynamic instability and significant alterations of coagulative tests, except for elevated D-Dimer and fibrinogen values, supported this hypothesis.

However, about 24 hours after extubation, the patient complained of severe abdominal pain, and a new episode of acute anemia occurred (Hb value  $<7$  g/dL). Abdominal ultrasound examination showed the presence of a large hematoma of the abdominal wall (left rectus muscle) without hemoperitoneum. Meanwhile, active bleeding began from the entry sites of venous and arterial lines. Total body CT (with and without contrast) was performed immediately and revealed a large active hematoma in the left rectus muscle without hemoperitoneum (Figure 1) and active bleeding in the cervical, mediastinal and inguofemoral sites.

According to clinical and imaging features, appropriate treatment for DIC, which was probably triggered by a laceration of the rectus abdominal muscle during pronation-supination, was done and consisted of blood products transfusions (plasma and red blood cells), fibrinogen, antithrombin III, coagulation factors. Moreover, cryotherapy was performed. Despite the rapid improvement in coagulation profile and clinical picture, the patient gas exchange worsened, requiring mechanical ventilation. A new CT was performed and showed that the hematomas were in resolution without active bleeding but an increase in lung consolidation was seen. The patient died a week later due to severe non-bleeding pancreatitis.

## Discussion

Emerging evidence showed that COVID-19 can be complicated with coagulopathy encompassing a broad spectrum of disorders.<sup>9</sup> COVID-19 must be considered a systemic disease injuring the vascular endothelium which causes highly activated coagulation cascade with extensive micro and macro-thromboses in the lung and other organs. Coagulation disorders related to COVID-19 may finally cause multiorgan failure, even when the patient is not of advanced age or predisposed by preexisting comorbidity.<sup>10</sup> Abnormal hemostasis can be recognized early in the profile of these patients: very elevated levels of serum D-dimer are a consistent finding which are associated with adverse outcomes.<sup>11</sup> D-dimer is a biomarker of fibrin formation and degradation, and its elevated level is the



**Figure 1.** The figure shows the large hematoma (red dotted arrow) in the left rectus muscle without hemoperitoneum.

most frequent abnormality in more than 70% of admitted patients without significant alternations in the levels of the remaining commonly measured hemostasis parameters (minimal prolongation of prothrombin time and mild reduction in platelet count, raised fibrinogen levels).

Preliminary data conducted on patients with severe COVID-19 have shown that anticoagulant therapy can be associated with lower mortality in the subpopulation meeting sepsis-induced coagulopathy criteria or markedly elevated D-dimer (D-dimer > 1500 ng/mL, normal range: 0-500 ng/ml).<sup>12</sup> Moreover, the D-dimer level can be used not only to predict thromboembolic events but also as a prognostic tool for risk stratification. According to the International Society on Thrombosis and Haemostasis (ISTH), hospital admission should be considered in patients with markedly raised D-dimers (arbitrarily defined as 3-4 fold increase) even in the absence of other symptoms suggesting disease severity, as this clearly signifies increased thrombin generation.<sup>13</sup>

Although thrombotic complications are recognized as one of the common characteristics of COVID-19, clinicians should be alert about the development of hemorrhagic events. Anticoagulation treatment must be carefully weighed against the risks of bleeding which are not insubstantial in critically ill patients. Shah et al<sup>5</sup> reported that 8.0% of patients experienced hemorrhagic complications, of which 4.8% were classified as major bleeding, defined as (i) fatal bleeding and/or; (ii) symptomatic bleeding in a critical area or organ (intracranial, intraspinal, intraocular, retroperitoneal, intraarticular or pericardial, or intramuscular with compartment syndrome), and/or (iii) bleeding causing a fall in Hb level of 2 g/dL or more or leading to transfusion of two or more units of whole blood or red blood cells.<sup>14</sup> Gastrointestinal bleeding was the most common site, followed by bleeding related to traumatic maneuvers. However, Fraissé et al<sup>15</sup> reported that 23% of hemorrhagic events in COVID-19 patients receiving anticoagulation therapies occurred in deep muscles being an occult bleeding site.

In our case, the active hematoma in the left rectus muscle was probably a complication of position changes during pronation in a patient receiving high-dose anticoagulation therapy (LWMH twice a day plus aspirin). Prone positioning ventilation to treat ARDS improves oxygenation, reduces ventilation-perfusion mismatch and gravity-related atelectasis. Prone positioning ventilation for no less than 12 hours daily can be considered a relatively safe procedure recommended for the treatment of COVID-19 related ARDS.<sup>6</sup> However, position changes during the maneuver are traumatic events, especially in curarised patients, and can cause muscle lacerations. The muscle damage in our patient under high-dose anticoagulant justified the slow formation of hematomas of the abdominal wall with the occurrence of anemia and consumption coagulopathy. Although bleeding and

hematoma were adequately treated with medical therapy, multiple transfusions of plasma and red blood cells accentuated inflammatory lung damage with the need for mechanical ventilation. Actually, no data were reported in the literature about hemorrhagic complications during/after prone position ventilation in critically COVID-19 patients.

After this clinical case and considering the specific significance of D-dimer level in critical patients, crucial questions remain to be addressed:

1. Should selected COVID-19 patients receive thromboprophylaxis, especially if they are immobilized and with additional prothrombotic factors?
2. Should all hospitalized patients with severe COVID-19 be treated with empirical intermediate or therapeutic-intensity anticoagulation?
3. Should antiplatelet therapies be added in selected cases?

### Conclusion

In summary, COVID-19-associated coagulopathy is still incompletely understood, and therapeutic options are limited to unspecific supportive therapy. All hospitalized COVID-19 patients should receive prophylactic anticoagulation therapy, yet a more aggressive individualized strategy might be required in critically ill patients. Even the addition of antiplatelet therapies should be considered due to the possibility of diffuse microthrombosis. But health care providers need to be cognizant of the increased incidence of bleeding in case of aggressive therapy, especially in hidden and unusual sites, and to be careful of all traumatic maneuvers carried out in ICU.

### Conflict of Interest

The authors declare no conflict of interest.

### Ethical Approval

For the present case report, the institutional review board (University of Naples Luigi Vanvitelli) waived the need for informed consent.

### Authors' Contribution

Conception and Design, R.C. De Rosa, M. Gallifuoco; Writing-Original draft preparation, R.C. De Rosa, A. Romanelli; Writing-Review & editing, R.C. De Rosa, A. Corcione; Supervision R.C. De Rosa; Project Administration, R.C. De Rosa.

### Funding

This research did not receive any specific grant from funding agencies in the public, commercial, or not-for-profit sectors.

### Reference

1. Cui S, Chen S, Li X, Liu S, Wang F. Prevalence of venous thromboembolism in patients with severe novel coronavirus pneumonia. *J Thromb Haemost.* 2020;18(6):1421-4. doi: 10.1111/jth.14830.

2. Malato A, Dentali F, Siragusa S, Fabbiano F, Kagoma Y, Boddi M, et al. The impact of deep vein thrombosis in critically ill patients: a meta-analysis of major clinical outcomes. *Blood Transfus.* 2015;13(4):559-68. doi: 10.2450/2015.0277-14.
3. Wang Y, Lu X, Li Y, Chen H, Chen T, Su N, et al. Clinical course and outcomes of 344 intensive care patients with COVID-19. *Am J Respir Crit Care Med.* 2020;201(11):1430-4. doi: 10.1164/rccm.202003-0736LE.
4. Iba T, Levy JH, Levi M, Connors JM, Thachil J. Coagulopathy of coronavirus disease 2019. *Crit Care Med.* 2020;48(9):1358-64. doi: 10.1097/ccm.0000000000004458.
5. Shah A, Donovan K, McHugh A, Pandey M, Aaron L, Bradbury CA, et al. Thrombotic and haemorrhagic complications in critically ill patients with COVID-19: a multicentre observational study. *Crit Care.* 2020;24(1):561. doi: 10.1186/s13054-020-03260-3.
6. Möhlenkamp S, Thiele H. Ventilation of COVID-19 patients in intensive care units. *Herz.* 2020;45(4):329-31. doi: 10.1007/s00059-020-04923-1.
7. Peng QY, Wang XT, Zhang LN. Using echocardiography to guide the treatment of novel coronavirus pneumonia. *Crit Care.* 2020;24(1):143. doi: 10.1186/s13054-020-02856-z.
8. Sikachi R, Agrawal A. Whole body point-care ultrasound for COVID-19: a multi-system approach to a multi-system disease. *Anaesthesia.* 2020;75(8):1114-5. doi: 10.1111/anae.15087.
9. Bikdeli B, Madhavan MV, Jimenez D, Chuich T, Dreyfus I, Driggin E, et al. COVID-19 and thrombotic or thromboembolic disease: implications for prevention, antithrombotic therapy, and follow-up: JACC state-of-the-art review. *J Am Coll Cardiol.* 2020;75(23):2950-73. doi: 10.1016/j.jacc.2020.04.031.
10. Tang N, Li D, Wang X, Sun Z. Abnormal coagulation parameters are associated with poor prognosis in patients with novel coronavirus pneumonia. *J Thromb Haemost.* 2020;18(4):844-7. doi: 10.1111/jth.14768.
11. Klok FA, Kruip M, van der Meer NJM, Arbous MS, Gommers D, Kant KM, et al. Incidence of thrombotic complications in critically ill ICU patients with COVID-19. *Thromb Res.* 2020;191:145-7. doi: 10.1016/j.thromres.2020.04.013.
12. Tang N, Bai H, Chen X, Gong J, Li D, Sun Z. Anticoagulant treatment is associated with decreased mortality in severe coronavirus disease 2019 patients with coagulopathy. *J Thromb Haemost.* 2020;18(5):1094-9. doi: 10.1111/jth.14817.
13. Thachil J, Tang N, Gando S, Falanga A, Cattaneo M, Levi M, et al. ISTH interim guidance on recognition and management of coagulopathy in COVID-19. *J Thromb Haemost.* 2020;18(5):1023-6. doi: 10.1111/jth.14810.
14. Schulman S, Kearon C. Definition of major bleeding in clinical investigations of antihemostatic medicinal products in non-surgical patients. *J Thromb Haemost.* 2005;3(4):692-4. doi: 10.1111/j.1538-7836.2005.01204.x.
15. Fraissé M, Logre E, Pajot O, Mentec H, Plantefève G, Contou D. Thrombotic and hemorrhagic events in critically ill COVID-19 patients: a French monocenter retrospective study. *Crit Care.* 2020;24(1):275. doi: 10.1186/s13054-020-03025-y.